

## CASE REPORT

## Aphakic pupillary block: A case study and review of the literature

Elinor Megiddo Barnir, Amir Hadayer, Noa Geffen, Alon Zahavi

Department of Ophthalmology, Rabin Medical Center – Beilinson Hospital, Petach Tikva; affiliated to Sackler Faculty of Medicine, Tel Aviv University, Tel Aviv, Israel

**Key words:**

Nd: YAG laser, pupillary block, vitreous prolapse

**Address for correspondence:**Alon Zahavi, Department of Ophthalmology,  
Rabin Medical Center – Beilinson Hospital,  
Petach Tikva 4941492, Israel.  
Tel.: +972-3-9376101.  
E-mail: alonzahavi@gmail.comReceived: 05-02-2018;  
Accepted: 09-04-2018  
doi: 10.15713/ins.clever.10**Abstract**

This study was aimed to describe a case study of a 75-year-old male patient with aphakic pupillary block. Angle-closure glaucoma is a sight-threatening condition. Pupillary block is often a component of angle-closure glaucoma that has multiple possible etiologies. Prolapse of vitreous through the pupillary aperture as a cause of pupillary block is uncommon. Although laser iridotomy is the mainstay treatment in pupillary block, it is not always an effective treatment strategy for this particular clinical scenario. A 75-year-old male presented to the emergency department with symptoms and signs compatible with aphakic acute angle closure secondary to vitreous prolapse through the pupillary aperture, causing pupillary block. The patient was treated with topical intraocular pressure (IOP) lowering agents and systemic hyperosmotics resulting in a moderate decrease in IOP. Treatment attempt to relieve the pupillary block component with Nd: YAG laser iridotomy was ineffective. The second attempt at Nd: YAG laser aimed at the vitreous bubble protruding through the pupillary aperture was successful, with immediate aqueous humor flow and deepening of the anterior chamber, IOP decrease, and resolution of symptoms. Anterior segment photographs and anterior segment optical coherence tomography (AS-OCT) scans obtained before and following the procedure were useful in evaluating and documenting the clinical scenario and eventual vitreous block resolution. We report an unusual case of vitreous pupillary block and treatment strategy using Nd: YAG laser vitreolysis. Anterior segment imaging, particularly AS-OCT, is a useful auxiliary test for evaluation and documentation in such complex cases.

**Introduction**

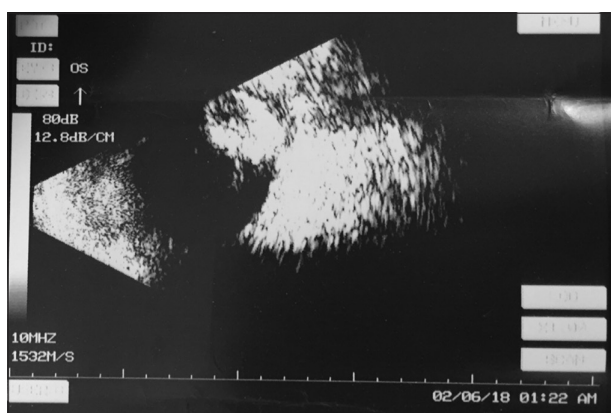
Angle-closure glaucoma is a sight-threatening condition which may result in irreversible blindness. Pupillary block is often a component of acute angle closure (AAC), which requires emergency treatment. Essentially, a prevention of aqueous flow from the posterior to the anterior chamber through the pupillary aperture, pupillary block may be caused by posterior synechiae, a crystalline or artificial lens, silicone oil, or vitreous substance.<sup>[1-5]</sup> Prolapse of vitreous through the pupillary aperture as a cause of pupillary block is uncommon and should be managed carefully. Although laser iridotomy is considered the mainstay of treatment in pupillary block,<sup>[6,7]</sup> it is not always an effective treatment strategy. Here, we present a case of an aphakic patient with vitreal pupillary block and its management.

Ophthalmologists should be aware of this condition and alternative treatment techniques.

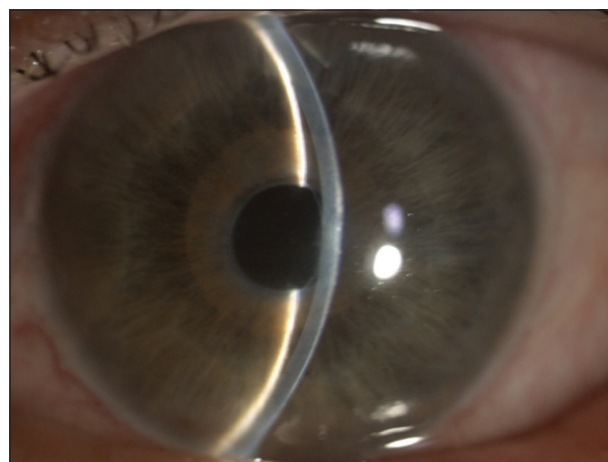
**Case Report**

A 75-year-old male presented to the emergency department with acute redness and pain in his left eye. Medical history included diabetes and hypertension. He reported poor vision in his left eye since childhood, estimated at hand motion, but was uncertain of the cause. Ophthalmologic evaluation of the right eye was unremarkable. Left eye visual acuity was hand motion, with an intraocular pressure (IOP) of 60 mmHg. Anterior segment examination demonstrated conjunctival hyperemia, corneal microcystic edema, and shallow anterior chamber with peripheral

iridocorneal touch, iris atrophy, and vitreous prolapsed through the pupillary aperture. Aphakia and a small hypoplastic optic disc with macular pallor and extensive chorioretinal atrophy were noted. An appositionally closed angle was seen on gonioscopy. Due to corneal edema and resulting difficulty in detailed posterior segment examination, ultrasound imaging of the left eye was performed that revealed an elliptic hyperechogenic finding in the inferior vitreous cavity adjacent to the retina, corresponding to a dropped crystalline lens [Figure 1]. Anterior segment photographs and anterior segment optical coherence tomography (Heidelberg Engineering GmbH, Heidelberg, Germany) (AS-OCT) were used to document the vitreous prolapse leading to pupillary block [Figures 2 and 3]. The patient was treated with topical IOP lowering agents including Cosopt (Dorzolamide 20 mg/ml, Timolol 5 mg/ml, Laboratoires Merck Sharp and Dohme - Chibret, France), Alphagan (Brimonidine tartrate 0.15%, Allergan, Inc. Irvine, CA, USA), Xalatan (Latanoprost 0.005%, Pfizer, USA), and pilocarpine (2%). 70 mg of oral Sorbitol



**Figure 1:** Ultrasound imaging of the left eye demonstrating an elliptic hyperdense finding in the inferior vitreous cavity adjacent to the retina, corresponding to a dropped crystalline lens

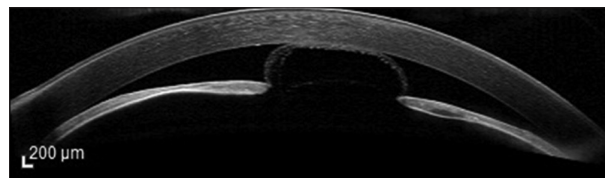


**Figure 2:** Anterior segment photograph showing peripheral iridocorneal touch, shallow anterior chamber, and a vitreous bubble prolapsed through the pupillary aperture touching the cornea

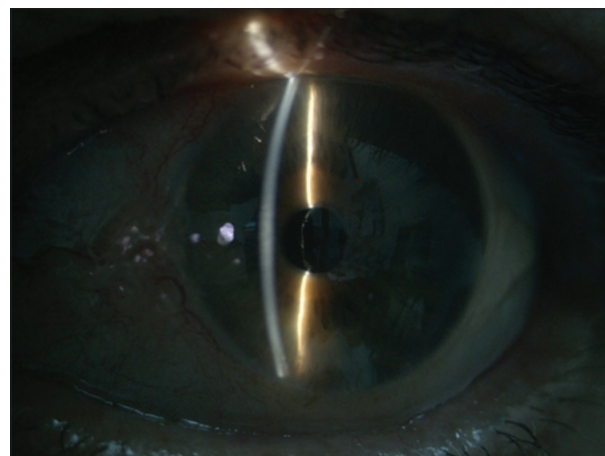
(Sorbitol, Pfizer) was administered. One hour later, IOP was still high at 50 mmHg, and 1.5 mg/kg body weight of intravenous Mannitol (Mannitol, Baxter, USA) was given. One hour later, IOP decreased to 30 mmHg. Treatment attempt to relieve the pupillary block component with Nd: YAG (neodymium-doped yttrium aluminum garnet) laser iridotomy was ineffective although a patent iridotomy was achieved. A second attempt at Nd: YAG laser aimed at the vitreal bubble protruding through the pupillary aperture was successful with immediate aqueous humor flow and deepening of the anterior chamber [Figure 4]. IOP decreased to 12 mmHg with resolution of the symptoms. The patient was discharged with dexamycin drops TID (Dexamethasone sodium phosphate 0.1%, Neomycin sulfate 0.5%, Vitamed Ltd., Israel). At 1-week follow-up, the patient was asymptomatic and reported improvement in vision with best-corrected visual acuity of counting fingers in his left eye. IOP measured 14 mmHg with a clear cornea and a deep anterior chamber.

## Discussion

Glaucoma is the leading cause of irreversible blindness worldwide.<sup>[8]</sup> A subtype of glaucoma AAC presents as an ophthalmic emergency which should be managed carefully. IOP lowering medical therapy is recommended as the initial step, followed by laser iridotomy to relieve the pupillary block



**Figure 3:** Anterior segment photographs and anterior segment optical coherence tomography showing peripheral iridocorneal touch, shallow anterior chamber, and a vitreous bubble prolapsed through the pupillary aperture



**Figure 4:** Anterior segment photograph post-laser vitreolysis showing a deep anterior chamber and vitreous prolapsed through the pupillary aperture

component often present in AAC.<sup>[7]</sup> While it is known that aphakic patients can present with AAC, as the vitreous substance hinders aqueous flow through the pupillary aperture, such reports are scarce in the literature. Waisoburd *et al.* reported a case of aphakic pupillary block which resolved after peripheral iridotomy.<sup>[9]</sup> A different case of vitreous prolapse into the anterior chamber following Nd: YAG capsulotomy, with ensuing pupillary block glaucoma managed by laser iridotomy, was reported by Li *et al.*<sup>[5]</sup>

Unlike previously reported cases, however, peripheral iridotomy failed to relieve the pupillary block component in our patient, presumably as the iridotomy aperture was immediately blocked by the vitreous substance. Nd: YAG laser vitreolysis of the vitreous substance protruding through the pupillary aperture was successful with immediate resolution of the angle-closure episode and normalization of the IOP.

AS-OCT is a very practical imaging tool that is being used with increasing frequency for the diagnosis and documentation of anterior segment pathology.<sup>[10]</sup> It provides a detailed image with high spatial resolution compared with other anterior segment imaging modalities such as ultrasound biomicroscopy. Moreover, it does not require water immersion or direct probe contact with the eye, reducing patient discomfort and image distortion. In the case presented, anterior segment photographs and AS-OCT scans obtained before and following the procedure were useful in evaluating and documenting the clinical scenario and eventual vitreous block resolution.

### Conclusion and Clinical Significance

We report an unusual case of vitreous pupillary block and treatment strategy using Nd: YAG laser vitreolysis. Anterior segment imaging, particularly AS-OCT, is a useful auxiliary test for evaluation and documentation in such complex cases. Ophthalmologists should be aware of the various treatment options available and the potential benefit of advanced imaging for diagnosis and documentation of such cases.

### References

1. Riedel KG, Gabel VP, Neubauer L, Kampik A, Lund OE. Intravitreal silicone oil injection: Complications and treatment of 415 consecutive patients. *Graefes Arch Clin Exp Ophthalmol* 1990;228:19-23.
2. Moorthy RS, Mermoud A, Baerveldt G, Minckler DS, Lee PP, Rao NA. Glaucoma associated with uveitis. *Surv Ophthalmol* 1997;41:361-94.
3. Liebmann JM, Ritch R. Glaucoma secondary to lens intumescence and dislocation. In: Ritch R, Shields MB, Krupin T, editors. *The Glaucomas*. 2nd ed. St Louis: Mosby; 1996.
4. Arriola-Villalobos P, Iglesias-Lodares I, Díaz-Valle D, Garcia-Gil-de-Bernabé J. Pupillary block acute glaucoma due to acrylic intraocular lens posterior dislocation after Nd:YAG capsulotomy. *Arch Soc Esp Oftalmol* 2011;86:300-2.
5. Li EY, Wu, WK, Jhanji V. Pupillary block glaucoma secondary to vitreous prolapse after Nd: YAG capsulotomy. *Clin Exp Optom* 2011;94:383-4.
6. Quigley HA. Long-term follow-up of laser iridotomy. *Ophthalmology* 1981;88:218-24.
7. Weinreb RN, Aung T, Medeiros FA. The pathophysiology and treatment of glaucoma: A review. *JAMA* 2014;311:1901-11.
8. Tham YC, Li X, Wong TY, Quigley HA, Aung T, Cheng CY. Global prevalence of glaucoma and projections of glaucoma burden through 2040: A systematic review and meta-analysis. *Ophthalmology* 2014;121:2081-90.
9. Waisbourd M, Hu WD, Affel E, Henderer JD, Mantravadi AV. Aphakic pupillary block. *JAMA Ophthalmol* 2015;133:e141821.
10. Ramos JL, Li Y, Huang D. Clinical and research applications of anterior segment optical coherence tomography - A review. *Clin Exp Ophthalmol* 2009;37:81-9.

**How to cite this article:** Barnir EM, Hadayer A, Geffen N, Zahavi A. Aphakic pupillary block: A case study and review of the literature. *Clin Exp Vis Eye Res J* 2018;1(1): 48-50.

This work is licensed under a Creative Commons Attribution 4.0 International License. The images or other third party material in this article are included in the article's Creative Commons license, unless indicated otherwise in the credit line; if the material is not included under the Creative Commons license, users will need to obtain permission from the license holder to reproduce the material. To view a copy of this license, visit <http://creativecommons.org/licenses/by/4.0/> © Barnir E.M, Hadayer A, Geffen N, Zahavi A. 2018